




<https://doi.org/10.47430/ujmr.2381.015>



Received: 13 May 2023

Accepted: 20 June 2023

## Case Report of Neonatal Echoviral Meningitis caused by Echovirus 30 at Aminu Kano Teaching Hospital Kano, Nigeria

Surayya Lawan Idris<sup>1</sup> , Nasir Tukur Dabo<sup>2</sup>, Abdulkadir M Magashi<sup>3</sup>, Zubaida Farouk Ladan<sup>4</sup>, Sakina Sani Buhari<sup>5</sup>, Amina Ibrahim<sup>6</sup>

<sup>1</sup>Department of Biological Sciences, Yusuf Maitama Sule University, Kano

<sup>2</sup>Department of Biological Sciences, Bayero University, Kano

<sup>3</sup>Department of Microbiology, Bayero University, Kano

<sup>4</sup>Centre for Infectious Disease Research, Bayero University, Kano

<sup>5</sup>Department of Biological Sciences, Aliko Dangote University of Science and Technology, Kano

<sup>6</sup>Influenza Diagnostic Laboratory, AKTH

Corresponding Author: [idrissurayyalawan@yahoo.com](mailto:idrissurayyalawan@yahoo.com)

### Abstract

*One of the most frequent causes of aseptic meningitis in infants, which is frequently lethal and has a high morbidity and mortality rate, is echovirus 30 (E30). This study reports the first case of neonatal meningitis caused by E30 at Aminu Kano Teaching Hospital (AKTH). The newborn was identified as having no fever, odd body movements, and respiratory distress. E30 was found in the neonate's cerebrospinal fluid (CSF) using reverse transcription real-time PCR. Phototherapy, antibiotics, and intravenous immunoglobulin (IVIG) were used to treat the newborn. The study stresses how aseptic meningitis symptoms and indications are non-specific, therefore doctors must be aware of babies' clinical state when treating bacterial infections in neonates.*

**Keywords:** Aseptic Meningitis, Echovirus 30, Cerebrospinal fluid, Neonate

### INTRODUCTION

The clinical illness known as aseptic meningitis is defined by meningeal inflammation in the cerebrospinal fluid (CSF) that is not brought on by a specific bacterial pathogen (Irani, 2008). According to Shaker and Abdelhamid (2015) and Olfat (2015), aseptic meningitis, which includes viral meningitis, is the most prevalent acute viral infection of the central nervous system (CNS) in children under the age of one. Even though its clinical course is similar to that of its bacterial counterpart, viral meningitis tends to be more common and causes 26,000 to 42,000 hospital admissions annually in the United States alone, placing a significant burden on the economy and society (Vandesande *et al.*, 2020). Viruses, bacteria, fungi, parasites, medications, systemic disorders, and other factors can all lead to aseptic meningitis (Kaur, 2022). Viruses are the most common cause of aseptic meningitis in children (Somayeh *et al.*, 2014).

In neonates and young children, enterovirus infections can vary from an acute, self-limiting febrile illness to meningitis, endocarditis, hepatitis, and acute flaccid myelitis, among other serious illnesses (Wells and Coyne, 2019). The mode of transmission is usually through

contact with droplets or secretions from a carrier and possible vertical transmission from mother to child (Kadambari, Braccio *et al.*, 2019). There are four species of enteroviruses: (3) Human enterovirus C (CVA1, A11, A13, A17, A19-A22, and A24; polioviruses 1-3; EV96); (4) Human enterovirus D (EV68 and EV70); and (5) Coxsackievirus [CV] A2-A8, A10, A12, A14, and A16 (EV71, 76, 89, 90, and 91) (Kim *et al.*, 2012). Poliovirus, coxsackieviruses, echoviruses, enterovirus 71, and enterovirus D68 are all members of the enterovirus genus. Early in their life cycles, enteroviruses predominantly target the gastrointestinal epithelium through the fecal-oral pathway (Wells and Coyne, 2019). Enteroviruses (EV) are the most frequent source of viral infection; Coxsackie and Echo viruses are responsible for more than half of all cases (Kumar 2005; Drysdale *et al.*, 2017). As single-stranded RNA viruses belonging to the Enterovirus genus and Picornaviridae family, echoviruses E30 may cause severe illness and even death in newborns. It is a significant pathogen linked to aseptic meningitis, which has been highly prevalent in recent decades all over the world in both adults and children (Ventura *et al.*, 2001).

There were several reports of Echo virus outbreak at neonatal units. (Sathish, Scott *et al.* 2004)

E30 was identified as the causative agent of an outbreak of aseptic meningitis in young infants in a Mossel Bay Hospital in the Western Cape region of South Africa (4/43) along with other Enteroviruses (EVs) serotypes (Smuts *et al.*, 2018). In a study conducted in Iran by Shabani *et al.* (2018), it was shown that neonates had a high incidence of EVs (39.06% overall), with E30 being present in 33.3% of the EVs positive specimens. Adolescents in Finland were affected by an outbreak of enteroviral aseptic meningitis; the underlying cause was determined to be E30 by virus specific RT-qPCR from enterovirus sensitive CSF (Osterback *et al.*, 2015). A 6-day-old kid who was admitted to the neonatal hospital with aseptic meningitis and was found to have the echovirus 30 (Bailey *et al.*, 2000) was also found to have an infected mother. Aseptic meningitis was found in 52.6% of cases (n=654) and E30, E9, CB3, and E33 were the most frequently isolated serotypes, according to research done between 1998 and 2003 at the Gutierrez Children's Hospital in Buenos Aires, Argentina (Mistchenko *et al.*, 2006). According to Miranda *et al.* (2006), E30 was the most isolated serotype that caused aseptic meningitis (AM) in Paris, France. Richer *et al.* (2006) established that EVs were the cause of aseptic meningitis AM in Cyprus; E30 was found in the CSF of 55% of patients, E6 (13.8%), and E9 (8.3%) with other coxsackie serotypes as rare etiologies.

#### **Case Presentation:**

A female term neonate was admitted to the Special Care Baby Unit (SCBU) at Aminu Kano Teaching Hospital (AKTH) a tertiary health centre at two days of life. The baby presented with focal convulsions, respiratory distress, and yellow discoloration of the eyes, which had persisted for 24 hours. The infant had suckled few hours after birth, but had progressively become lethargic and unresponsive. The mother was a 20-year-old primipara with no maternal risk factors for sepsis. No genital warts in the mother and no history of rashes. Her group B streptococcus carrier status is not known. The neonate had cried spontaneously after birth, and no other significant perinatal history was reported.

#### **Clinical Examination:**

Upon examination, the neonate's core body temperature was 36.1°C, and severe respiratory distress, the respiratory rate was 68 cycles per minute, oxygen saturation (SPO<sub>2</sub>) was 86% in room air. The pulse rate was 160 beats per minutes. Additionally, the baby exhibited focal

seizures, and all primitive reflexes were depressed. There was bulging of the fontanel. The neonate was unresponsive to stimuli, raising clinical suspicion of meningitis.

#### **Laboratory results:**

According to unit protocol sepsis workup was done including a lumbar puncture, The cerebrospinal fluid (CSF) appeared crystal clear and was under pressure, but showed significant abnormalities, with a leukocyte (WBC) count of 23,300/mm<sup>3</sup>, comprising 15,900/mm<sup>3</sup> granulocytes and 6,000/mm<sup>3</sup> lymphocytes. CSF culture yielded no bacterial growth, and the latex agglutination test was negative for bacterial antigens. The bacterial blood culture using BACTECT was also negative. However, using qRT-PCR, Echovirus 30 was isolated from the CSF, confirming the diagnosis of Echovirus meningitis.

#### **Case Management:**

The neonate's seizure was initially treated with intravenous phenobarbital and calcium gluconate, but no response was observed. To address potential complications and provide supportive care, intramuscular Vitamin B12 (1mg) was administered. Additionally, empirical intravenous antibiotics were initiated, including Salbactam ampicillin (200mg/kg) and Amikacin (25mg/kg), in line with the unit's protocol and intravenous immunoglobulin. The baby also received supplemental oxygen at FiO<sub>2</sub> 40% to maintain adequate oxygen saturation.

#### **Short term Clinical Outcome:**

On the fifth day of hospitalization, the neonate's condition showed significant improvement. Oxygen saturation was 98%, and laboratory parameters, including white blood cell count, red blood cell count, mean platelet volume, and bilirubin levels, were within the normal range. The neonate was alert, responsive, and free from seizures, leading to her discharge from the hospital.

This case report highlights the significance of considering viral etiologies, particularly enteroviruses and Echovirus, when evaluating neonates presenting with meningitis symptoms. Early identification and appropriate management are crucial for favorable outcomes. The diagnosis of Echovirus meningitis in this neonate was confirmed using qRT-PCR, underlining the importance of specialized testing in such cases. Possible infection with cytomegalovirus, toxoplasmosis and other congenital infections can be identified by screening mother during ANC, and also by serological test, but PCR remain gold standard for identifying specific viral etiology, which we were able to do in this case.

Hitherto, many cases of aseptic meningitis remained un-identified and might be labelled as bacterial meningitis or other encephalopathies. Risk factors for might include maternal history of STI, such as genital herpes, drug abuse. There was no identified possible risk factor in this case. This neonate presented with respiratory distress, typically within 3 to 5 days of life(John 1986), echo viral infection can present with sepsis like symptoms including severe respiratory distress(Zhang, Wang *et al.* 2021). This neonate was initially treated with empirical antibiotics for the first 72 hours according to protocol. The use of antibiotics in suspected meningitis is recommending prior to obtaining culture result. This neonate had supportive management following negative CSF and blood cultures including intravenous immunoglobulin. There is

no FDA approved anti-viral drug against Echoviruses, no anti- viral drug was given. The successful management, with resolution of symptoms and normalization of laboratory parameters, following supportive treatment provided.

Echovirus meningitis can be a serious condition in neonates, but prompt diagnosis and appropriate management can lead to positive outcomes. This case emphasizes the importance of vigilant monitoring, supportive care, and considering viral etiologies when dealing with neonates presenting with neurological symptoms at a tertiary health center in Nigeria. Further research and awareness are necessary to understand the epidemiology and clinical implications of Echovirus infections in this vulnerable population.

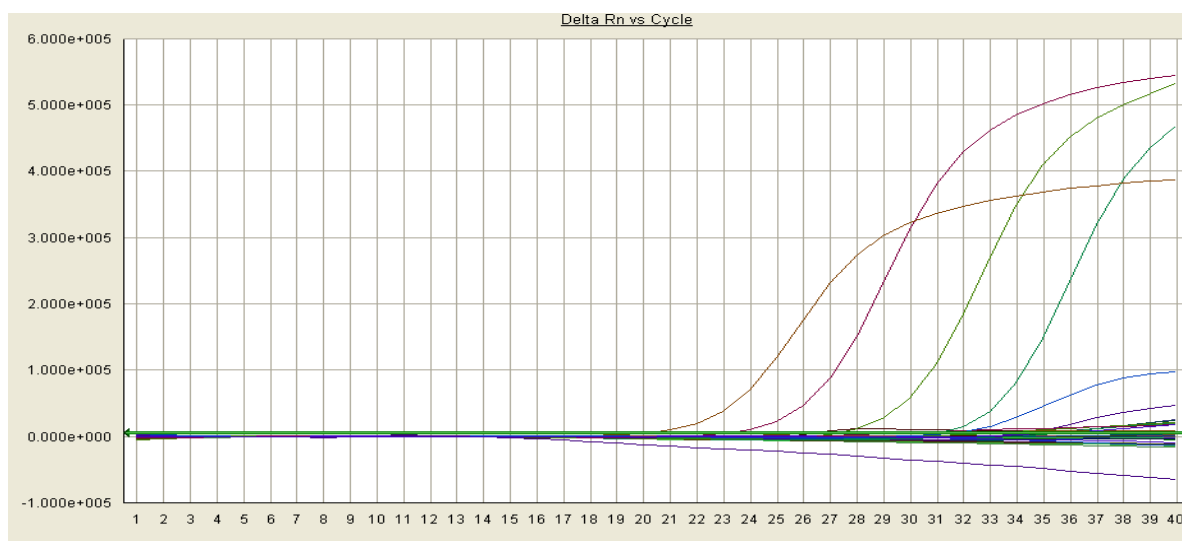


Figure 1: E30 Detection and Viral Load Amplification Plot 1.X-axis- Number of amplification Cycles, Y-axis- Amount of amplified Product in the Tube.

## DISCUSSION

This study reports the first case of early-onset of neonatal echovirus 30 meningitis in a neonate with respiratory distress from AKTH, Kano, Nigeria. The study findings indicated that some cases of meningitis in neonates in the study area could be due to echovirus but might be missed if laboratory was un able to detect viral particles in the CSF. This is because PCR the gold standard for viral identification might not be readily available in many hospitals in LMIC like Nigeria. Furthermore, many families pay for healthcare out of pocket, with endemic poverty, they cannot afford additional cost of such test. Occurrence of infections especially in neonates is not surprising as neonates are at

risk of infection due to immaturity of their immune system and vertical transmission from mothers.

Diagnosis of E30 in this neonate was confirmed by PCR. The infection was treated with IVIG with good clinical outcomes; the vital signs, some hematological parameters and white blood cell counts were normal on the fifth day of treatment. Yen *et al.* (2015) also reported effectiveness of intravenous immunoglobulin in treatment of neonatal viral meningitis. Li *et al.* (2019) noted that in the absence of specific antiviral treatment, attention needs to be taken while treating neonatal infection as enteroviral infections have a poorer prognosis in neonates than in older children.

*UJMR, Vol. 8 No. 1, June, 2023, pp 122-126.*

Neonatal echoviral infection leads to disseminating-/systemic infection that could simulate bacterial sepsis. This emphasizes need for continues research of pathogens including viral agents, among neonates with clinical sepsis.

## CONCLUSION

The study reports the first case of Neonatal Echoviral Meningitis in Kano State, Nigeria. The study identified the need for prompt diagnosis and treatment to avoid systemic dissemination of the virus.

## REFERENCES

- Bailly, J.L., Beguet, A., Chambon, M., Henquell, C. & Peigue-lafeuille, H. (2000). Nosocomial Transmission of Echo-virus 30: Molecular Evidence by Phylogenetic Analysis of the VP1 Encoding sequence. *Journal of Clinical Microbiology*; 38 (8): P2889-2892. [\[Crossref\]](#)
- Chen, C., Tsao, P., Chou, H., Hsieh, W., Huang, L. (2003). Severe Echovirus 30 Infection in Twin Neonates. *J Formos Med Assoc.*;102(1): 59-61.
- Drysdale, S.B. and Kelly, D. (2017). Fifteen-minute consultation: enterovirus meningitis and encephalitis- when can we stop the antibiotics? *Arch Dis Educ Pract Ed.* 102(2): 66-71. [\[Crossref\]](#).
- Irani, DN. (2008). Aseptic Meningitis and Viral Myelitis. *Neurology Clinic*; 26(3): 635. [\[Crossref\]](#)
- John, F. M. (1986). "Perinatal Echovirus Infection: Insights from a Literature Review of 61 Cases of Serious Infection and 16 Outbreaks in Nurseries." *Reviews of Infectious Diseases* 8(6): 918-926. [\[Crossref\]](#)
- Jie, L., Wang, J., Yang, M., Jiang, F. (2019). A Case Report of Neonatal Meningitis and Myocarditis caused by Enterovirus. *Academic Journal of Paediatrics and Neonatology*;8(4): AJPN.MS.ID.555797. [\[Crossref\]](#)
- Kadambari, S., et al. (2019). "Enterovirus and parechovirus meningitis in infants younger than 90 days old in the UK and Republic of Ireland: a British Paediatric Surveillance Unit study." *Arch Dis Child* 104(6): 552-557. [\[Crossref\]](#)
- Kaur, H., Betances, E.M., Perera, T.B. (2022). Aseptic meningitis. *Treasure Island. Statpearls publishing.*

*E-ISSN: 2814 – 1822; P-ISSN: 2616 – 0668*

## Acknowledgment

The authors recognize the assistance rendered by the numerous physicians, clinicians, and the Lab technologies at AKTH.

## Funding

The authors have not received any funding for the design of the study or for specimen collection, analysis, and interpretation of data or for writing the manuscript.

## Conflict of Interest

The authors declare that there is no conflict of interests regarding the publication of this paper.

Kim, H.J., Kang, B., Hwang, S., Hong, J., Kim, K. and Cheon, D.S. (2012). Epidemics of viral meningitis caused by Echovirus 6 and 30 in Korea in 2008. *Virology*; 9 :38. [\[Crossref\]](#)

Kumar, R. (2005) Aseptic meningitis: Diagnosis and management. *Indian Journal of Paediatrics*; 72: 57. [\[Crossref\]](#)

Mistchenko, A.S., Viegas, M., Latta, M.P. and Barrero, P.R. (2006). Molecular and epidemiologic analysis of enterovirus B neurological infection in Argentina children. *J Clin Virol*; 37(4): 293-9. [\[Crossref\]](#).

Olfat M., Silverman, E.D. and Levy, D.M. (2015). Rituximab therapy has a rapid and durable response for refractory cytopenia in childhood onset systemic lupus erythematosus. *Lupus*;24(9): 966-72. [\[Crossref\]](#)

Osterback, R., Kalliokoski, T., Lahdesmaki, T., Peltola V., Ruuskanen, O. and Wavis M. (2015). Echovirus 30 meningitis epidemic followed by an outbreak-specific RT-qPCR. *J Clin Virol.*; 69:7-11. [\[Crossref\]](#)

Richter, J., Koptides, D., Tryfonos, C. and Christodoulou, C. (2006). Molecular typing of enteroviruses associated with viral meningitis in Cyprus, 2000-2002. *J Med Microbiol.*; 55 (8): 1035-41. [\[Crossref\]](#)

Shabani, A., Mmakvandi, M., Samarbafzaden, A., Teimoon, A., Rast, i M., Karami, C., Rastegarvand, N., Nikfar, R., Shamsizaden, A., Salehi, A. and Angali, K.A. (2018). Echovirus 30 and Coxsackievirus A9 Infection among young neonates with sepsis in Iran. *Iranian Journal of Microbiology*; 10 (4):258-265.

Shaker, O.G. and Abdelhamid, N. (2014). Detection of enteroviruses in paediatric

- patients with aseptic meningitis. *Clinical Neurology and Neurosurgery*; 129:67-71. [[Crossref](#)]
- Sathish, N., et al. (2004). "An outbreak of echovirus meningitis in children." *Indian pediatrics* 41(4): 384-388.
- Smuts, H., Cronje, S., Thomas, J., Bank, D., Korsman, S. and Hardie, D. (2018). Molecular characteristics of an outbreak of Enterovirus- associated meningitis in Mossel Bay South Africa, December 2015- January 2016. *BMC Infect Dis*; 18(1):709. [[Crossref](#)]
- Vandesande, H., Mira Laajala, M., Kantoluoto, T., Ruokolainen, V., Lindberg, A.M., and Marjomäki, V. (2020). Early Entry Events in Echovirus 30 Infection. *Journal of Virology*; 94(13): e00592-20. [[Crossref](#)]
- Ventura, K.C., Hawkins, H., Smith, M.B. and Walker, D.H. (2001). Fatal Neonatal Echovirus 6 Infection: Autopsy Case Report and Review of the Literature. *Modern Pathology*; 14:85-90. [[Crossref](#)]
- E-ISSN: 2814 – 1822; P-ISSN: 2616 – 0668*
- Wells, A. and Coyne, C.B. (2019). Enteroviruses: A Gut-Wrenching Game of Entry, Detection, and Evasion. *Viruses*; 11, 460; [[Crossref](#)]
- Yen, M., Huang, Y., Chen, M., Liu, C., Chiu, N., Lien, R., Chang, L., Chiu, C., Chiu, C., Tsao, K. and Lin, T. (2015). Effectiveness of Intravenous Immunoglobulin for neonates with Severe Enteroviral Infections with Emphasis on the Timing of Administration. *J Clin Virol.*;64:92-6. [[Crossref](#)]
- Zhao, Y.N., Jiang, Q.W, Jiang, R.J., Chen, L., and Perlin, D.S. (2005). Echovirus 30, Jiangsu Province, China. *Emerging Infectious Diseases*; 11(4):562-567. [[Crossref](#)]
- Zhang, M., et al. (2021). "Clinical characteristics of severe neonatal enterovirus infection: a systematic review." *BMC Pediatrics* 21(1): 127. [[Crossref](#)]